Complications of Arthroscopic Drilling in the Treatment of Osteochondritis Dissecans of the Knee in Children and Adolescents

Soroush Baghdadi, MD[1], David Isaacs[1,2], Calvin Chan[1], Lawrence Wells, MD[1], Theodore J Ganley, MD[1], John Todd Lawrence, MD, PhD[1]

[1]Children's Hospital of Philadelphia Division of Orthopaedics, PA, USA

[2]University of Pennsylvania, PA, USA

INTRODUCTION

- Osteochondritis Dissecans (OCD) is a condition where the subchondral bone is affected and may lead to damage to the articular cartilage[5]
- Primarily affects athletic, pediatric populations[4]
- Reported incidence of 9.5 to 29 per 100,000 in pediatric population for OCD of the knee[1,4]
- Treatment varies from conservative approaches such as bracing and activity modification to drilling for stable intact lesions and fixation or cartilage restoration procedures for unstable lesions[2]
- Drilling is pursued generally 3 to 12 months after conservative treatment fails[3]
- Drilling has higher success rate than both nonoperative treatment and other surgical treatments[6,7]
- While the efficacy of drilling is established, there is a paucity of information specifically evaluating its risks and complications

Arthroscopic transarticular drilling of stable OCD lesion in the knee

Adapted from Kocher, Tucker, Ganley, & Flynn et al 2006

OBJECTIVES

- **Purpose**: This study seeks to evaluate children and adolescents undergoing arthroscopic drilling to determine the complication rate and assess how and when the patients return to their usual daily activity

METHODS

- Retrospective review through the CHOP Epic system to gather data from patients presenting to its tertiary care pediatric orthopedic surgery center from May 2009 through July 2017
- Used Current Procedure Terminology (CPT) code 29886 to identify patients with arthroscopic drilling of intact OCD of the knee
- Exclusion criteria included patients that were over 18 years old, had under 3 months of follow up, had associated lesions, or underwent an additional procedure for an OCD on the same knee
- Collected demographic data, duration of nonoperative treatment, size of lesion, type of anesthesia, drilling technique, and data on postoperative recovery
- Complications were defined as stiffness, reoperation, pain, and infection during the postoperative period
- Analysis included standard descriptive statistics, student's t-tests, Mann-Whitney U test, and chi-square tests

RESULTS

- Cohort:
  - 139 knees, 131 patients
  - 102 (73%) were male
  - 52% right knee and 48% left knee
  - Mean age was 12.7 years (range, 9-18)
  - 37 patients (28.2%) had bilateral symptoms, 21 (16%) had bilateral lesions, 8 had bilateral drilling
- Treatment Data

Mean duration of nonoperative treatment	Average size of lesion	Mean time to full range of motion	Mean time to return to sports
6.76 months	2.35cm^2	12.9 weeks*	20.9 weeks

*all patients obtained full range of motion after surgery

  - Anesthesia: 24 (17.2%) of surgeries were general anesthesia (GA) alone and 115 (82.8%) were GA with a nerve block
  - Type of drilling: 127 knees (91%) used transarticular and 12 knees (9%) used retroarticular
- Complications
  - No cases of infection, stiffness, arthrofibrosis
  - 2 knee (1%) were painful at latest follow-up
  - 6 knees (4%) combined for 7 additional surgeries due to treatment failure in non-healing lesions, rather than complications of the initial drilling

Gender/Age at initial surgery	Details of Reoperation	Outcome
F/10	Pain and locking developed 20 months post surgery. Reoperation performed 2 years after the index surgery for loose body removal and repeat drilling.	No pain, full return to activities
F/12	Underwent bilateral drilling initially with resolution of symptoms. 9 months post surgery, pain and popping developed. MRI showed a non-healing lesion. Another drilling and loose body removal procedure 2 years after the index surgery occurred.	Full resolution of symptoms bilaterally
M/12	The patient had bilateral OCDs, and MFC and LFC in the left knee. Initially healed but 2 years later pain developed due to non-healing of the MFC lesion. Underwent repeat drilling and removal of frayed cartilage 2.5 years after the index surgery.	Mild, intermittent pain in the left knee without mechanical symptoms. Full return to activities.
M/14	Underwent staged, bilateral drilling, with full return to sports. 2.5 years post surgery, pain and locking in left knee developed. Patient had loose body removal, debridement and microfracture of the denuded cartilage and subchondral bone.	Minimal pain and no mechanical symptoms.
M/14	1 year post surgery, pain developed due to a non-healing lesion. Underwent repeat drilling and debridement of the frayed cartilage 2 years after index surgery.	No pain or mechanical symptoms, returned to previous sports
M/17	Pain and limping did not resolve after surgery. MRI showed progression of the lesion and underwent chondroplasty of the non-viable cartilage 2 years after the index procedure. Underwent ACI 7 months later at another institution.	Has moderate pain and experiences clicking and locking. Scheduled for surgery due to overgrowth of the ACI graft

Table 1. Details of the patients who underwent reoperation. OCD: osteochondritis dissecans, MFC: medial femoral condyle, LFC: lateral femoral condyle, ACI: autologous chondrocyte implantation

CONCLUSION/DISCUSSION

- Only size of lesion was associated with reoperation
  - Size of lesion significantly larger in patients who required further surgical intervention (3.33 cm^2 vs 2.31 cm^2) (P-value=0.037)
  - Patients with OCD larger than 2.5cm^2 were 5.1 times more likely to require reoperation (P-value=0.024)
- No complications specifically attributable to surgical procedure itself
  - All reoperation cases were due to non-healing lesions
  - Of those who's lesions healed, only 1 patient had any pain in knee at latest follow up
- All patients regained full ROM, 93% by 3 month visit
- Relevant for physicians debating the risks of surgical intervention
  - Minimal risk of complication complication
  - May prevent physicians from avoiding an effective surgical intervention due to concern about complications

X-ray of 12 y/o male with an OCD on medial femoral condyle

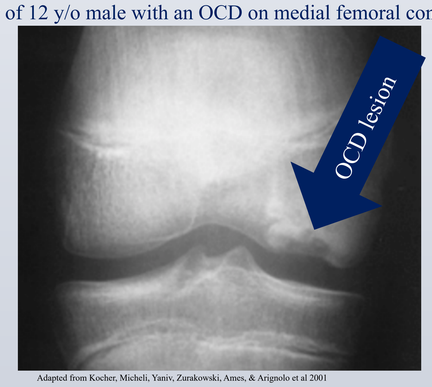

Adapted from Kocher, Micheli, Yaniv, Zurakowski, Ames, & Arignolo et al 2001

LIMITATIONS

- Functional outcomes of surgeries were not assessed
- Indications for and duration of nonoperative treatment were not standardized
- Long term complications post fully recovery and discharge from CHOP may have been missed

REFERENCES

1. Ananthaharan A, Randsborg P-H. Epidemiology and patient-reported outcome after juvenile osteochondritis dissecans in the knee. The Knee. 2018;25(4):595-601.
2. Edmonds EW, Polousky J. A review of knowledge in osteochondritis dissecans: 123 years of minimal evolution from König to the ROCK study group. Clinical Orthopaedics and Related Research®. 2013;471(4):1118-26.
3. Eismann EA, Pettit RJ, Wall EJ, Myer GD. Management Strategies for Osteochondritis Dissecans of the Knee in the Skeletally Immature Athlete. *Jounral of Orthopaedic & Sports Physical Therpay*. 2014;44(9):665-679. https://www.jospt.org/doi/10.2519/jospt.2014.5140
4. Kessler KI, Nikizad H, Shea KG, Jacobs JC Jr, Bebchuk JD, Weiss JM. The demographics and epidemiology of osteochondritis dissecans of the knee in children and adolescents. *Am J Sports Med.* 2014;42(2): 320-326. doi: 10.1177/0363546513510390.
5. Kumar V, Nhatnagar S, Lodhi JS. Grade I Osteochondritis Dissecans in a Young Professional Athelte. *Indian J Orthop.* 2018;52(4): 344-352. doi:10.4103/ortho.IJOrtho_322_17.
6. Pascual-Garrido, Cecilia & G McNickle, Allison & J Cole, Brian. Surgical Treatment Options for Osteochondritis Dissecans of the Knee. *Sports Health*. 2016;1(4):326-34. 10.1177/1941738109334216.
7. Masquijo J, Kothari A. Juvenile osteochondritis dissecans (JOCD) of the knee: current concepts review. *Effort Open Reviews*. 2019;4(5):201-212. 10.1302/2058-5241.4.180079